37 3D Imaging: SPACE

When MR was in its infancy, 2D spin echo (SE) imaging was the most commonly used scan technique. SE imaging was robust to artifacts from magnetic field inhomogeneities, an advantage with early magnets. Three-dimensional spin echo imaging was possible but failed to gain widespread acceptance due to extremely long scan times. A potential advantage of such an acquisition would be the possibility of retrospectively reconstructing high spatial resolution images in any orientation from a single scan acquisition. With the advent of turbo or fast spin echo imaging (these two terms are interchangeable and are abbreviated TSE and FSE), 3D imaging became feasible. However, power deposition with 3D FSE is high and indeed prohibitive in some instances, particularly at 3 T. In the past few years, several variants of FSE technique have been introduced, with the objective being to reduce the power absorbed by the patient. All achieve a decrease in SAR by reducing in some fashion the flip angle of the refocusing pulse in the FSE sequence. One such technique, termed TRAPS (transition between pseudo steady states), employs a train of variable refocusing flip angles in an arrangement such that the echoes close to the center of k space are fully refocused. Modifying this approach by using a flip angle series that yields a constant signal for the majority of the spatially encoding echo train, taking into account the relaxation during data sampling, will further improve image quality. This optimization requires knowledge of the relaxation values for the tissue to be imaged. This complex approach, with application-specific flip angle evolution, achieves the desired contrast using ultralong echo trains in combination with a 3D FSE imaging acquisition scheme and has been termed SPACE (sampling perfection with application optimized contrasts by using different flip angle evolutions). This method provides for the necessary reduction in SAR, taking advantage of a volume acquisition and optimizing the achievable CNR for a specific application. Images with proton density, T1- or T2-weighting can be achieved, as well as FLAIR-like contrast for brain and cord imaging.

Fig. 37.1

Figure 37.1 illustrates a T2-weighted SPACE acquisition in the cervical spine. The scan time was 6 minutes (using a parallel imaging factor of 3) with

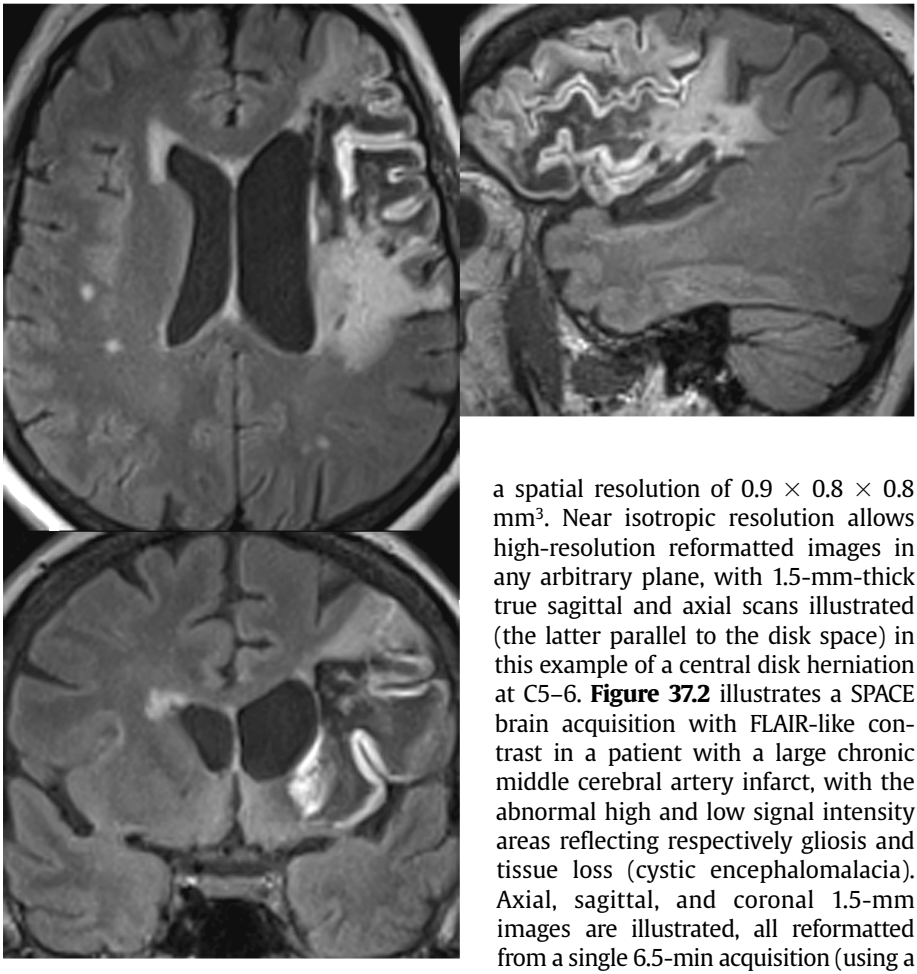

Fig. 37.2

a spatial resolution of 0.9 × 0.8 × 0.8 mm^3. Near isotropic resolution allows high-resolution reformatted images in any arbitrary plane, with 1.5-mm-thick true sagittal and axial scans illustrated (the latter parallel to the disk space) in this example of a central disk herniation at C5–6. **Figure 37.2** illustrates a SPACE brain acquisition with FLAIR-like contrast in a patient with a large chronic middle cerebral artery infarct, with the abnormal high and low signal intensity areas reflecting respectively gliosis and tissue loss (cystic encephalomalacia). Axial, sagittal, and coronal 1.5-mm images are illustrated, all reformatted from a single 6.5-min acquisition (using a parallel imaging factor of 2) with 1 × 1 × 0.9 mm^3 voxel dimensions.

Examining the SPACE technique in more detail, nonselective refocusing pulses are used to achieve ultrashort echo spacing (as low as 3 msec). This permits in part echo train lengths > 300, with the result (when used in combination with parallel imaging) being high-resolution 3D image acquisition within an acceptable scan time. This approach is clinically advantageous in particular in areas of complex anatomic detail, including applications in the spine, musculoskeletal system (knee, meniscus), and brain (internal auditory canal). For detection of small lesions, such as MS plaques, SPACE has been shown to be superior to thin section (3 mm) 2D imaging.